



## EVALUATION OF MORPHOLOGICAL CHANGES IN BONE TUNNELS AFTER ACL RECONSTRUCTION: A SYSTEMATIC REVIEW

**Nizamettin Güzel<sup>i</sup>**

Samsun Training and Research Hospital,  
Department of Orthopedics and Traumatology,  
Samsun, Türkiye

### **Abstract:**

This study aimed to gain a comprehensive understanding of the morphologic changes in femoral and tibial bone tunnels after ACLR, various graft types, fixation techniques, and their effects on graft maturation and clinical outcomes. From January 2014 to September 2023, a literature search was performed in the PubMed database using the terms "ACL reconstruction", "morphological change" and "tunnel" and "imaging" or "CT" or "computed tomography" or "MRI" or "magnetic resonance imaging" or "radiography". Only full-text published articles were included, with no language preference. In 11 studies, the criteria for examining the morphologic changes in the tunnels after ACLR were classified according to the graft methods used, tibial and femoral tunnel measurements, and imaging methods, and the results of healing and morphologic changes in the tunnels were examined. When the results of the studies were evaluated in general, it was concluded that healing and proper morphology in the tunnels were associated with graft health and tunnel width. Therefore, it was concluded that the most appropriate healing and morphologic shape would be obtained by determining the points to be opened well before tunneling and placing the graft in the most proper and anatomical way.

**Keywords:** ACL reconstruction, morphology, tunnel widening, graft type

### **1. Introduction**

Anterior cruciate ligament reconstruction (ACLR) is a widely performed orthopedic procedure and is of significant interest because of the morphologic changes in the femoral and tibial tunnels after surgery and their impact on graft maturation and clinical outcomes. Morphologic changes in the femoral and tibial bone tunnels after ACLR have been the focus of extensive research due to their impact on graft maturation and long-term clinical outcomes. Studies have investigated various aspects of tunnel changes,

<sup>i</sup> Correspondence: [nizamettin.guzel@saglik.gov.tr](mailto:nizamettin.guzel@saglik.gov.tr)

including its correlation with hamstring tendon autograft maturation, bone tunnel widening, and the effect of different graft types and fixation techniques.

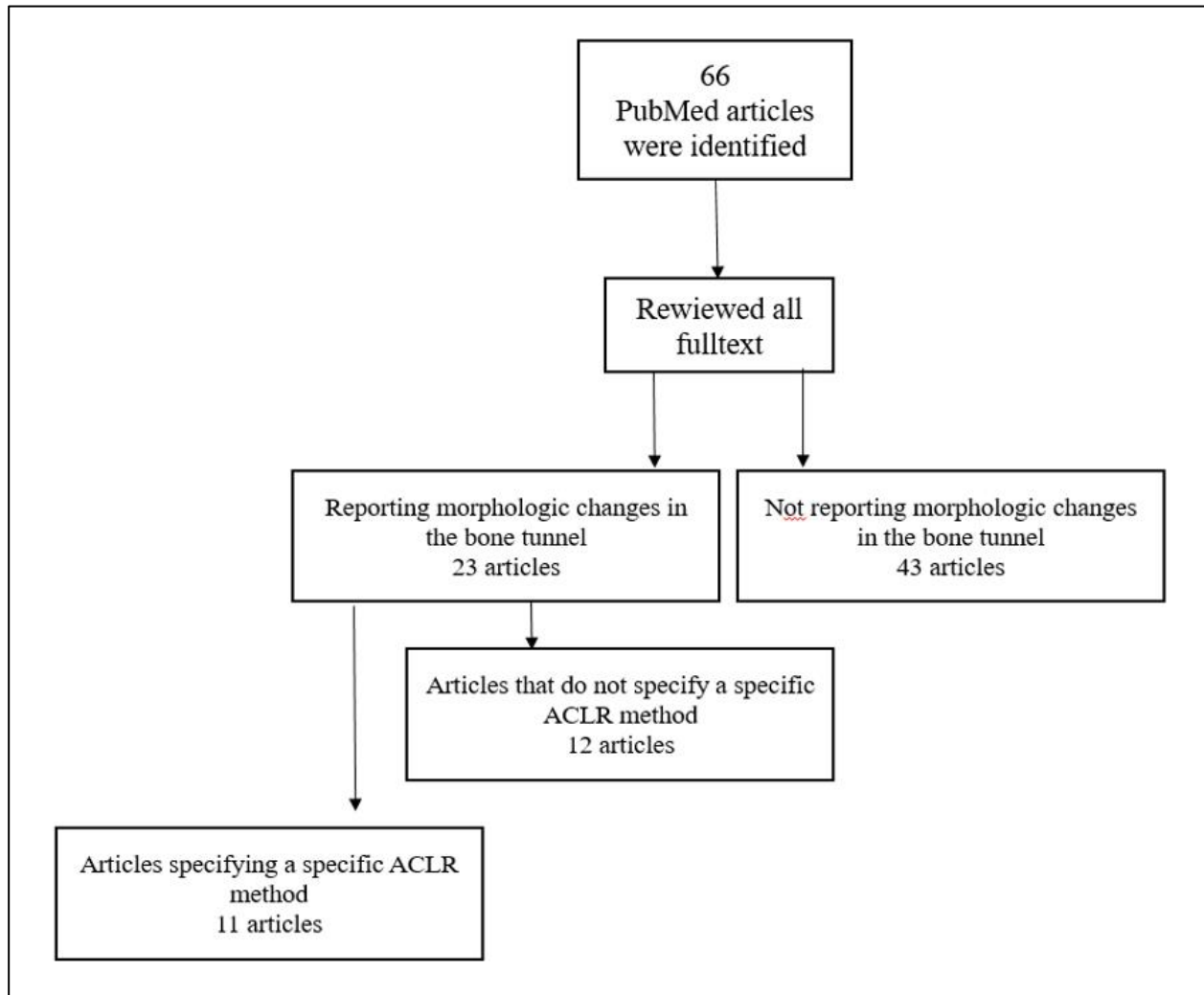
Morphological changes in the femoral and tibial bone tunnels over a 2-year follow-up period with the use of anatomical single-bundle ACLR calcium phosphate hybridized tendon grafts have been studied, providing valuable information on the long-term outcomes of this particular graft type (Uchida R. et al., 2018). In addition, the correlation between morphologic changes of the femoral tunnel and hamstring tendon autograft maturation up to 2 years after ACLR using femoral cortical suspension was investigated, shedding light on the relationship between tunnel changes and graft healing (Zhang S. et al., 2020). In a study examining the effects of calcium phosphate hybridized tendon grafts on morphological changes in femoral and tibial bone tunnels, the long-term results of anatomical single-bundle ACLR were also shed light on (Mutsuzaki H. et al., 2023). Furthermore, comparisons have been made between different fixation methods such as extracortical and anatomical fixation to evaluate tunnel widening and its effects on postoperative healing (Buelow J. U. et al., 2002).

In addition to femoral tunnel changes, studies have also examined morphological changes in the tibial tunnel after ACLR, emphasizing the importance of understanding bone healing and volumetric changes in the tibial tunnel, especially with the outside-in technique and adjustable sling fixation (Okutan A. E. et al., 2023). Furthermore, investigations into the effects of soft tissue interposition and postoperative sling cortical button migration on functional outcomes and ligamentization after single-bundle ACLR have provided valuable information on potential complications and their management (Özbek E. A. et al., 2022). Furthermore, critical reviews have been conducted to assess bony tunnel widening after ACLR, providing a comprehensive overview of the factors influencing tunnel widening and its clinical outcomes (Morgan J. A. et al., 2012). A recent study by Campos et al. also examined the effect of ACLR techniques on tunnel widening and coalition, contributing to the understanding of surgical approaches and their effects on tunnel morphology (Campos T. et al., 2023). In addition, studies have focused on the use of osseous landmarks for anatomical ACL femoral tunnel placement and emphasized the importance of precise tunnel positioning for optimal surgical outcomes (Brown C. H. et al., 2013). Furthermore, the effects of residual tissue preservation on tunnel enlargement after anatomic double-bundle ACLR have been investigated, providing information on potential strategies to reduce tunnel enlargement and improve graft outcomes (Zhao S. et al., 2020).

In conclusion, the systematic review and synthesis of these studies provides a comprehensive understanding of the morphologic changes in femoral and tibial bone tunnels after ACLR, the various graft types, fixation techniques, and their effects on graft maturation and clinical outcomes.

## 2. Method

From January 2014 to September 2023, a literature search was performed in the PubMed database using the terms "ACL reconstruction", "morphological change" and "tunnel" and "imaging" or "CT" or "computed tomography" or "MRI" or "magnetic resonance imaging" or "radiography". No language preference was made and only full-text published articles were included. The literature search including the aforementioned search criteria identified 66 studies for potential inclusion; abstracts and full text for all these articles were subsequently reviewed and screened for inclusion (Figure 1). 49 were excluded because they did not report morphologic changes in the bone tunnel. In the remaining 11 studies, the criteria for examining morphologic changes in the tunnels after ACLR were classified according to the graft methods used, tibial and femoral tunnel measurements, and imaging methods, and the results of healing and morphologic changes in the tunnels were examined.



**Figure 1:** Flow chart of inclusion and exclusion criteria

**Table 1:** List of morphological results of bone tunnels according to different ACLR and tunnel measurement methods

Study	ACLR method	Tunnels measured	Views	Results
Mutsuzaki et al. (2019)	Calcium phosphate (CaP)-hybridized tendon graft	Tibial - Femoral	CT	Femoral bone tunnels did not enlarge at 2-year follow-up. Tibial bone tunnels widened at 1-year follow-up but decreased at 2-year follow-up.
Okutan et al. (2023)	Full tibial tunnel technique and cortical sling fixation with adjustable ring	Tibial	CT	At 6 months after ACLR, an average of 63.2% of the tibial tunnel was filled with bone, whereas after 1 year the tibial tunnel was almost completely closed.
Tachibana et al. (2014)	Anatomic triple-bundle (ATB)	Femoral	3D-CT	Femoral tunnel widening occurred at the opening but not in the middle of the femoral tunnel.
Uchida et al. (2018)	Bone-patellar tendon-bone (BPTB)	Tibial - Femoral	3D-CT Multiplanar Reconstruction (MPR)	Both femoral and tibial tunnel aperture were significantly enlarged distally and posterolaterally 6 months postoperatively.
Ohori et al. (2017)	ATB	Tibial	3D-CT	The posterior tibial tunnel was significantly enlarged at the aperture by 40% with the morphological change in the PM direction reflected by the ACL fiber orientation 1 year after the ATB ACL reconstruction.
Weber et al. (2015)	Arthroscopic ACLR	Tibial - Femoral	Serial MRI Sagittal, coronal	Tunnel expansion after ACL-R occurs early and primarily at the tunnel apertures.
Lee et al. (2014)	Trans-tibial Outside-in double-bundle	Femoral	Serial CT Sagittal, coronal	Widening was observed in both planes of both tunnels in the two techniques. Distances from the centre point to each four sections showed an increase in all four sections of all both tunnels in both techniques.
Zhang et al. (2020)	Femoral cortical suspension	Femoral	3D MR	The femoral bone tunnel was enlarged at 6 months and shrunk at 24 months.
Lee et al. (2014)	Trans-tibial	Femoral	Serial CT Sagittal, coronal	In some aspects, occurrence of tunnel widening was observed in most sites. Widening occurred mainly at the entrance and mid-portions of the anteromedial (AM)

				tunnel and the entrance of the posterolateral (PM) tunnel.
Mutsuzaki et al. (2018)	CaP-hybridized tendon graft unhybridized tendon graft	Femoral-tibial	3D-CT	As compared with the conventional method, the CaP-hybridized tendon graft reduced bone tunnel enlargement on the femoral side 1 year after anatomic single-bundle ACLR.
Taketomi et al. (2014)	Bone-patellar tendon-bone greft (BPTBR) Double-bundle reconstruction (DBR)	Tibial	3D-CT Sagittal	The femoral posterolateral tunnel aperture in DBR showed significantly more widening than did the AM tunnel aperture in DBR and the femoral tunnel aperture in BPTBR.

### 3. Discussion

Morphologic changes in tunnels after ACLR are important considerations in understanding the long-term outcomes and potential complications of the procedure. Many studies have investigated these changes and shed light on various aspects of tunnel morphology after reconstruction. This study includes studies examining morphologic changes in tunnels after ACLR using different graft methods, tibial and femoral tunnel measurements, and imaging modalities.

Lee et al. discussed the change in tunnel configuration in non-anatomic trans-tibial double-bundle ACLR and found widening in both planes of both tunnels in both techniques, and the distances from the center point to all four sections increased in all four sections of both tunnels in both techniques (Lee Y. S. et al., 2014). This result emphasized the importance of understanding the specific changes in tunnel configuration associated with different reconstruction techniques. In a different study, Lee et al. compared femoral tunnel widening between external-to-internal and trans-tibial double-bundle ACLR and provided insight into changes in tunnel morphology depending on the surgical approach (Lee Y. S. et al., 2014). In some respects, tunnel widening was observed to occur at most sites. Widening occurred mainly at the entrance and middle portions of the anteromedial tunnel and at the entrance of the posterolateral tunnel. These studies provide important information about changes in tunnel morphology after reconstruction, which is vital for understanding the long-term effects of the surgical procedure (Aga C. et al., 2016; Brown C. H. et al., 2013).

Taketomi et al. examined eccentric femoral tunnel widening in ACLR and found that the femoral posterolateral tunnel opening in DBR widened significantly more than the AM tunnel opening in DBR and the femoral tunnel opening in BPTBR, emphasizing the importance of precise tunnel placement to avoid such morphological changes (Taketomi S. et al., 2014; Celik H. et al., 2019). Uchida et al. and Otori et al. provided information on the relationship between bone plug position and morphologic changes of

tunnel patency, showing that both femoral and tibial tunnel patency widened significantly distally and posterolaterally 6 months and 1 year after surgery (Uchida R. et al., 2019; Ohori T. et al., 2017). With this result, the importance of correct positioning during ACLR is further emphasized (Baumfeld J. A. et al., 2008; Nakase J. et al., 2021).

Furthermore, Weber et al. presented a prospective longitudinal MRI study on tibial and femoral tunnel changes after ACLR, providing valuable insights into the temporal aspect of tunnel morphological changes and emphasizing that tunnel enlargement after ACLR occurs early and primarily at the tunnel openings (Weber A. E. et al., 2015). This longitudinal perspective is crucial for understanding the evolution of tunnel morphology over time and provides a comprehensive understanding of the long-term effects of ACLR (Yahagi Y. et al., 2023).

Existing studies, which provide valuable information on potential strategies to reduce tunnel widening and preserve tunnel morphology after reconstruction, investigated the effect of calcium phosphate hybridized tendon grafts on reducing femoral bone tunnel widening in anatomic single-bundle ACLR and discussed the morphological changes in femoral and tibial bone tunnels after anatomic single-bundle ACLR using calcium phosphate hybridized tendon graft, respectively. As a result, no widening of the femoral bone tunnel was observed at 2-year follow-up, whereas the tibial bone tunnels widened at the 1-year follow-up but decreased at the 2-year follow-up (Mutsuzaki H. et al., 2018; Mutsuzaki H. et al., 2019). In addition, Zhang et al. investigated the morphologic changes of the femoral tunnel and their correlation with hamstring tendon autograft maturation and found that the femoral bone tunnel widened at 6 months and shrank at 24 months (Zhang Y. et al., 2020). Month and shrank at 24 months, providing valuable information about the relationship between graft maturation and tunnel morphology after reconstruction (Zhang Y. et al., 2020; Manderle B. J. et al., 2021).

In conclusion, studies examining tunnel morphology after ACLR have revealed different results with different approaches according to different grafts and imaging. In general, the common opinion is that healing and proper morphology in the tunnels are associated with graft health and tunnel width. Therefore, it is thought that determining the points to be opened well before tunneling and placing the graft in the most proper and anatomical way will give the most appropriate healing and morphologic shape.

### **Conflict of Interest Statement**

The author declares no conflicts of interest.

### **About the Author**

Nizamettin Güzel works as a Specialist Doctor in the Department of Orthopedics and Traumatology at Samsun Training and Research Hospital, Turkey. His research interests include sports surgery, arthroplasty, trauma, and vertebral surgery.

## References

- Aga, C., Wilson, K. J., Johansen, S., Dornan, G., La Prade, R. F., & Engebretsen, L. (2017). Tunnel widening in single-versus double-bundle anterior cruciate ligament reconstructed knees. *Knee Surgery, Sports Traumatology, Arthroscopy*, 25, 1316-1327.
- Baumfeld, J. A., Diduch, D. R., Rubino, L. J., Hart, J. A., Miller, M. D., Barr, M. S., & Hart, J. M. (2008). Tunnel widening following anterior cruciate ligament reconstruction using hamstring autograft: a comparison between double cross-pin and suspensory graft fixation. *Knee Surgery, Sports Traumatology, Arthroscopy*, 16, 1108-1113.
- Brown, C. H., Spalding, T., & Robb, C. (2013). Medial portal technique for single-bundle anatomical anterior cruciate ligament (ACL) reconstruction. *International orthopaedics*, 37, 253-269.
- Buelow, J. U., Siebold, R., & Ellermann, A. (2002). A prospective evaluation of tunnel enlargement in anterior cruciate ligament reconstruction with hamstrings: extracortical versus anatomical fixation. *Knee Surgery, Sports Traumatology, Arthroscopy*, 10(2), 80-85.
- Campos, T., Perucci, M., Gomes, P., & Giordano, V. (2023). Combined reconstruction of medial collateral ligament and posterior cruciate ligament using one femoral tunnel: a technical note and case report applicable to limited-resource settings. *BMJ Case Reports*, 16(3), e252877.
- Celik, H., & Lee, D. H. (2019). Comparison of the aperture and midportion femoral tunnel widening after anterior cruciate ligament reconstruction: a systematic review and meta-analyses. *Medicine*, 98(26).
- Lee, Y. S., Lee, B. K., Oh, W. S., & Cho, Y. K. (2014). Comparison of femoral tunnel widening between outside-in and trans-tibial double-bundle ACL reconstruction. *Knee Surgery, Sports Traumatology, Arthroscopy*, 22, 2033-2039.
- Lee, Y. S., Oh, W. S., & Chun, D. I. (2014). Change of the tunnel configuration in the non-anatomic trans-tibial double bundle ACL reconstruction. *The Knee*, 21(3), 757-762.
- Manderle, B. J., Beletsky, A., Gorodischer, T., Chahla, J., Cancienne, J. M., Vadhera, A. S., ... & Verma, N. N. (2021). Transtibial Anterior Cruciate Ligament Reconstruction: Tips for a Successful Anatomic Reconstruction. *Arthroscopy Techniques*, 10(12), e2783-e2788.
- Morgan, J. A., Dahm, D., Levy, B., Stuart, M. J., & MARS Study Group. (2012). Femoral tunnel malposition in ACL revision reconstruction. *The journal of knee surgery*, 361-368.
- Mutsuzaki, H., & Kinugasa, T. (2023). Anatomical Single-Bundle Anterior Cruciate Ligament Reconstruction Using a Calcium Phosphate-Hybridized Tendon Graft with More than an Average of 5 Years of Follow-Up: A Follow-Up Study of a Randomized Controlled Trial. *Journal of Clinical Medicine*, 12(13), 4437.
- Mutsuzaki, H., Kinugasa, T., Ikeda, K., & Sakane, M. (2018). Calcium phosphate-hybridized tendon grafts reduce femoral bone tunnel enlargement in anatomic

- single-bundle ACL reconstruction. *Knee Surgery, Sports Traumatology, Arthroscopy*, 26, 500-507.
- Mutsuzaki, H., Kinugasa, T., Ikeda, K., & Sakane, M. (2019). Morphological changes in the femoral and tibial bone tunnels after anatomic single-bundle anterior cruciate ligament reconstruction using a calcium phosphate-hybridized tendon graft in 2 years of follow-up. *Orthopaedics & Traumatology: Surgery & Research*, 105(4), 653-660.
- Nakase, J., Takata, Y., Shimosaki, K., Asai, K., Yoshimizu, R., Kimura, M., & Tsuchiya, H. (2021). Clinical study of anatomical ACL reconstruction using a rounded rectangular dilator. *BMC Musculoskeletal Disorders*, 22(1), 1-8.
- Ohori, T., Mae, T., Shino, K., Tachibana, Y., Sugamoto, K., Yoshikawa, H., & Nakata, K. (2017). Morphological changes in tibial tunnels after anatomic anterior cruciate ligament reconstruction with hamstring tendon graft. *Journal of Experimental Orthopaedics*, 4(1), 1-10.
- Okutan, A. E., Gürün, E., Surucu, S., Kehribar, L., & Mahiroğulları, M. (2023). Morphological Changes in the Tibial Tunnel After ACL Reconstruction With the Outside-In Technique and Adjustable Suspensory Fixation. *Orthopaedic Journal of Sports Medicine*, 11(3), 23259671231155153.
- Özbek, E. A., Kocaoğlu, H., Karaca, M. O., Terzi, M. M., Dursun, M., & Akmeşe, R. (2022). Effect of Soft Tissue Interposition and Postoperative Suspensory Cortical Button Migration on Functional Outcomes and Ligamentization After Single-Bundle ACL Reconstruction. *Orthopaedic Journal of Sports Medicine*, 10(9), 23259671221122748.
- Tachibana, Y., Mae, T., Shino, K., Kanamoto, T., Sugamoto, K., Yoshikawa, H., & Nakata, K. (2015). Morphological changes in femoral tunnels after anatomic anterior cruciate ligament reconstruction. *Knee Surgery, Sports Traumatology, Arthroscopy*, 23, 3591-3600.
- Taketomi, S., Inui, H., Sanada, T., Yamagami, R., Tanaka, S., & Nakagawa, T. (2014). Eccentric femoral tunnel widening in anatomic anterior cruciate ligament reconstruction. *Arthroscopy: The Journal of Arthroscopic & Related Surgery*, 30(6), 701-709.
- Uchida, R., Shiozaki, Y., Tanaka, Y., Kita, K., Amano, H., Kanamoto, T., ... & Horibe, S. (2019). Relationship between bone plug position and morphological changes of tunnel aperture in anatomic rectangular tunnel ACL reconstruction. *Knee Surgery, Sports Traumatology, Arthroscopy*, 27, 2417-2425.
- Weber, A. E., Delos, D., Oltean, H. N., Vadasdi, K., Cavanaugh, J., Potter, H. G., & Rodeo, S. A. (2015). Tibial and femoral tunnel changes after ACL reconstruction: a prospective 2-year longitudinal MRI study. *The American journal of sports medicine*, 43(5), 1147-1156.
- Yahagi, Y., Iriuchishima, T., Iwama, G., Suruga, M., Morimoto, Y., & Nakanishi, K. (2023). Femoral Tunnel Length in Anatomical Double-Bundle Anterior Cruciate Ligament Reconstruction Is Correlated with Body Size and Knee Morphology. *The Journal of Knee Surgery*. Retrieved from <https://pubmed.ncbi.nlm.nih.gov/37739027/>



- Zhang, S., Liu, S., Yang, L., Chen, S., Chen, S., & Chen, J. (2020). Morphological changes of the femoral tunnel and their correlation with hamstring tendon autograft maturation up to 2 years after anterior cruciate ligament reconstruction using femoral cortical suspension. *The American Journal of Sports Medicine*, 48(3), 554-564.
- Zhang, Y., Liu, S., Chen, Q., Hu, Y., Sun, Y., & Chen, J. (2020). Maturity progression of the entire anterior cruciate ligament graft of insertion-preserved hamstring tendons by 5 years: a prospective randomized controlled study based on magnetic resonance imaging evaluation. *The American Journal of Sports Medicine*, 48(12), 2970-2977.
- Zhao, J. (2020). Anatomical single-bundle transtibial anterior cruciate ligament reconstruction. *Arthroscopy techniques*, 9(9), e1275-e1282.

Nizamettin Güzel  
EVALUATION OF MORPHOLOGICAL CHANGES IN BONE  
TUNNELS AFTER ACL RECONSTRUCTION: A SYSTEMATIC REVIEW

---

Creative Commons licensing terms

Author(s) will retain the copyright of their published articles agreeing that a Creative Commons Attribution 4.0 International License (CC BY 4.0) terms will be applied to their work. Under the terms of this license, no permission is required from the author(s) or publisher for members of the community to copy, distribute, transmit or adapt the article content, providing a proper, prominent and unambiguous attribution to the authors in a manner that makes clear that the materials are being reused under permission of a Creative Commons License. Views, opinions and conclusions expressed in this research article are views, opinions and conclusions of the author(s). Open Access Publishing Group and European Journal of Public Health Studies shall not be responsible or answerable for any loss, damage or liability caused in relation to/arising out of conflicts of interest, copyright violations and inappropriate or inaccurate use of any kind content related or integrated into the research work. All the published works are meeting the Open Access Publishing requirements and can be freely accessed, shared, modified, distributed and used in educational, commercial and non-commercial purposes under a [Creative Commons Attribution 4.0 International License \(CC BY 4.0\)](https://creativecommons.org/licenses/by/4.0/).